

ESTABLISHMENT OF A RAT MODEL OF TEMPOROMANDIBULAR JOINT OSTEOARTHRITIS USING INTRAARTICULAR INJECTION OF COMPLETE FREUND'S ADJUVANT

Dwi Merry Christmarini Robin, Dentistry Faculty, University of Jember,
Jl. Kalimantan 37 Jember, merrychristmarini@gmail.com

INTRODUCTION

Osteoarthritis is a common progressive joint disease, involving not only the joint lining but also cartilage, ligaments, and bone. Osteoarthritis (OA) of the temporomandibular joint is a unilateral, degenerative disease of the jaw joint. It is characterized by breakdown of the articular cartilage, architectural changes in bone, and degeneration of the synovial tissues causing pain and/or dysfunction in functional movements of the jaw. Temporomandibular joint osteoarthritis (TMJ OA) is an important etiology of temporomandibular pain. The temporomandibular joint (TMJ) undergoes degenerative changes among patients who suffer from arthritis, and yet the pathogenesis of TMJ osteoarthritis and rheumatoid arthritis is poorly understood. However, until recent years, OA of the temporomandibular joint was confusing, relatively unrecognized, and difficult to diagnose and manage and the specific mechanisms of TMJ OA in the development of temporomandibular pain are still not clear. Animal models are useful tools for the investigation of association between animal behavioral and TMJ OA. Several animal models of TMJ OA have been established using intraarticular injection of various chemicals. This study aimed to establish a rat model of TMJ OA using complete Freund's adjuvant (CFA). Histopathological change with hematoxylin-eosin staining and radiographic change of the TMJ was performed. Treatment with CFA induced cartilage damage, synovitis, and proliferation of synovial cells in the fact joints. A rat model of TMJ OA was successfully established using intraarticular injection of CFA. This animal model is convenient and shows good resemblance to human OA pathology. We hypothesized that inflammation in the TMJ induces structural abnormalities, and accordingly characterized the disc and synovium in a novel model with double injections of complete Freund's adjuvant (CFA), using histopathological change with hematoxylin-eosin staining and radiographic examination.

METHODS

In total, twenty ten-week-old male Sprague-Dawley rats (wt, 200-250 g) were randomly assigned to the experimental or control group (N = 10/group). The rats were anesthetized intraperitoneally with a ketamine and xylazine mixture. Osteoarthritis was induced with an intraarticular injection of 50 μ l of Complete Freund's adjuvant (CFA), (oil/saline at a ratio of 1:1) into the bilateral TMJs using a 30-gauge needle and 1-mL syringe. Rats in the control group received saline injections (same volume). All rats were housed under controlled temperature, on a 12-hour light/dark cycle with access to food and water. The experimental protocols were approved by the Animal Ethics Committee. The heads of the rats were dissected from euthanized rats on day three (10 rats in the case and 10 rats in the control groups). The separated heads were fixed in 10% formalin and were then carefully oriented in the paraffin blocks. The TMJ was removed and fixed in 4% paraformaldehyde and demineralized in 15% EDTA. The specimens were dehydrated in graded concentrations of alcohol and xylene, embedded in paraffin, and cut serially into 4 μ m sagittal sections. Next, they were stained with hematoxylineosin.

RESULTS

Time-course of Inflammation and Behavioral Assessment
Intense swelling and redness over the TMJ region were observed 1 day after the first CFA injection, but not in the saline injection group. The linear head width between bilateral TMJs showed marked increases in the inflammation group. Swelling gradually subsided within ~7 days following the first CFA injection, and showed no visual differences between experimental and control groups upon euthanasia at Day 21.

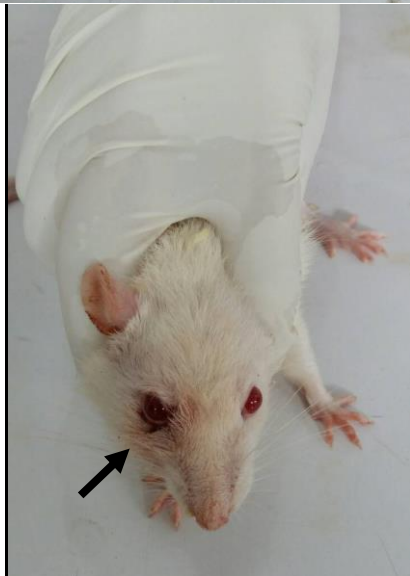
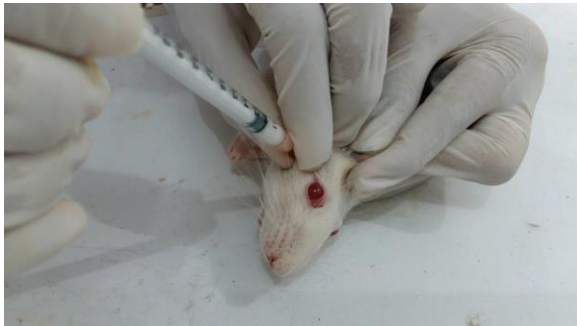
Figure 1. The clinical of TMJ OA of rat

Radiographic features

OA includes a low-inflammatory condition with multifactorial etiology and various radiological pictures, which is similar to osteoarthritic conditions in other synovial joints in the body. Degenerative bone changes include various changes in soft and hard tissues of TMJ. There are more stages of development of OA, which are characterized by structural bone change of the contours of the articular surfaces in various stages (moderate shape loss, severe sclerosation). After the initial stages with pronounced sclerosed areas and shape loss with outgrowths of osteophytes, development of subchondral pseudocyst is also significantly more frequent in the TMJs with OA.

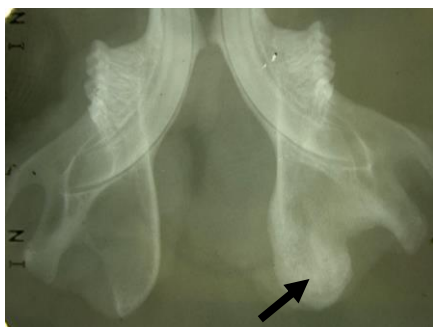


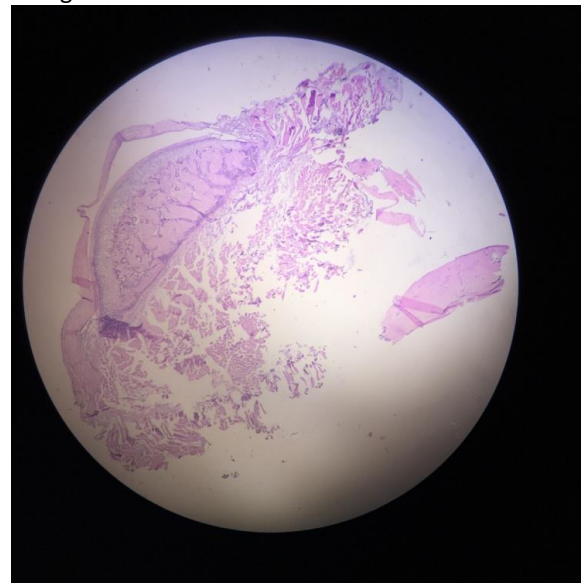
Figure 2. TMJ OA of rat

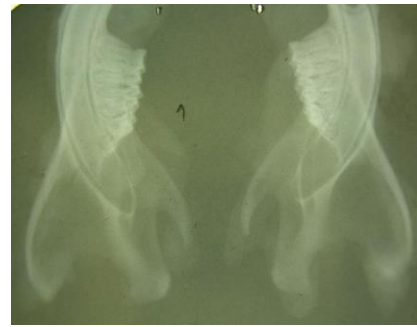

Figure 3. Control group

Histopathologic features

HE staining showed proliferation of the synovial cells, lymphocyte infiltration, and degenerative changes in the cartilage in the OA group. The second CFA injection (Day 14) was administered in consideration that TMJ inflammation may be exacerbated by repeated physical or chemical insults. Upon tissue harvest, the representative synovium in controls was thin and sufficiently transparent to reveal muscle color underneath. In contrast, the representative synovium in the experimental group was opaque and thickened. The representative control TMJ disc was largely transparent and thin, showing the typical anterior band, intermediate zone, and posterior band. In contrast, the inflamed TMJ disc was thickened and deformed and showed several characteristic changes.



DISCUSSION

There has been previously reported rat models of TMJ OA established using intraarticular injection of collagenase and monosodium iodoacetate.. In our study, we tried to establish a rat model of TMJ OA using intraarticular injection of complete Freund's adjuvant (CFA). CFA is a **Complete Freund's Adjuvant (CFA)** consists of heat-killed

Mycobacterium tuberculosis in non-metabolizable oils (paraffin oil and mannide monooleate). CFA contains trehalose 6,6' dimycolate (TDM), which stimulates Mincle. Additionally, CFA has ligands for TLR2, TLR4, and TLR9. CFA can be used to produce water-in-oil emulsions of antigens. Injection of antigen in CFA induces a **Th1-dominated response** when compared to injection in Incomplete Freund's Adjuvant (IFA), which lacks mycobacterial components and induces a Th2-dominated response. It has been found that CFA plays important roles in the degeneration of extracellular matrix in the osteoarthritic cartilage⁶, and levels of CFA in the articular cartilage and synovium are associated with the severity of cartilage damage¹⁸. Regarding the pathological roles of CFA in OA, we speculate that CFA might be a good candidate for the establishment of animal models of TMJ OA. The primary discovery was that TMJ synovium and disc undergo degenerative changes following sustained inflammation, based on an experimental design with 3 areas of improvement over previous work. First, double CFA injections, for the first time, were shown to induce reproducible, sustained inflammation. Second, comprehensive analyses characterized a model that may be used broadly for TMJ studies. Third, sustained inflammation yielded aberrant structural, cellular, and molecular changes in TMJ disc and synovium

The primary discovery was that TMJ synovium and disc undergo degenerative changes following sustained inflammation, based on an experimental design with 3 areas of improvement over previous work. First, double CFA injections, for the first time, were shown to induce reproducible, sustained inflammation. Second, comprehensive analyses characterized a model that may be used broadly for TMJ studies. Third, sustained inflammation yielded aberrant structural, cellular, and molecular changes in TMJ disc and synovium. These degenerative changes included deformation, thickening, increases in wet and net weights, increased cellularity, increased iNOS and IL-1 β expression, and significant increases of collagen type I and aggrecan contents, in addition to infiltration of mononucleated cells and abundant adipose tissue in the synovium. Aberrant changes in the structure of extracellular matrix and associated alterations of disc mechanical properties can surpass the adaptive capacity of disc and lead to clinically observed perforation (Kuribayashi *et al.*, 2008; Stegenga, 2010). Interestingly, head withdrawal threshold lacked any significant differences between the CFA and control groups after 35 days, suggesting that pain did not chronically persist. Thus, the observed structural deterioration may be independent of pain-induced

activities such as altered muscle contraction patterns.

The most striking increases in cellularity in the TMJ disc were in the anterior and intermediate bands, which readily experience compressive loading during mastication. Previously, TMJ cell proliferation had been associated with sustained inflammation (Takahashi *et al.*, 2003; Kristensen *et al.*, 2008). Besides cellularity, increases in disc thickness may be accounted for by matrix characteristics. Type I collagen is the predominant component of the extracellular matrix in the TMJ disc in humans and rats (Kalpakci *et al.*, 2011). GAG binds to type I collagen in the disc and serves to accumulate tissue fluid (Allen and Athanasiou, 2006). The increased collagen content may be accounted for by the increased cellularity and is likely a hypertrophic response (Abubaker *et al.*, 1996; Okazaki *et al.*, 1996). CFA has been injected into the superior joint compartment in the present and other studies (Harper *et al.*, 2001; Guan *et al.*, 2005; Spears *et al.*, 2005; Flake *et al.*, 2006). In the present study, we observed few phenotypic changes in condylar cartilage. In contrast, osteoarthritic changes have been reported to take place in condylar cartilage and subchondral bone, including clefts and erosions, when CFA is injected into the inferior joint compartment (Cledes *et al.*, 2006; Kuroki *et al.*, 2011). Comparison of temporal phenotypes of double CFA injections in the superior and inferior compartments is warranted.

Sustained inflammation is characterized by up-regulation of pro-inflammatory cytokines. In this work, IL-1 β and iNOS were up-regulated, suggesting that sustained inflammation in the TMJ is global, not only in the synovium, which is rich in vascular supply, but also in the avascular disc, similar to patients with TMJ arthritis (Suzuki *et al.*, 2002). IL-1 β and iNOS promote the synthesis of type I collagen in chondrocytes and fibroblasts (Elias *et al.*, 1990; Lertchirakarn *et al.*, 1998), which may partially account for the elevated collagen content. Although it is impossible to couple gross morphological changes directly to molecular events, we demonstrate that the HWT, a common behavioral assessment for the TMJ, shares a time-course similar to that of swelling and matrix changes in the inflamed TMJ disc and synovium. HWT is inversely associated with TMJ inflammation and pain (Ren, 1999), and is directly related to CFA injections. Although induced TMJ inflammation may decrease after ~14 days, inflammatory mediators persist for up to 6 wks (Kuroki *et al.*, 2011). The repeated intra-articular CFA administration in the present work is based on our pilot experiments in which inflammatory reactions upon single injection were insufficient to induce sustained inflammation. In

short, analysis of the present data is consistent with our hypothesis that sustained inflammation may be a predisposing factor for TMJ degeneration. To date, few tissue engineering studies of the TMJ have been performed in inflamed TMJ models. Improved understanding of TMJ degeneration and inflammation will enrich our knowledge of pathogenesis of TMJ arthritis and help design clinically relevant strategies for tissue engineering.

CONCLUSION

In conclusion, we successfully established a rat model of TMJ OA using intraarticular injection of CFA. This animal model is convenient and shows good resemblance of human facet joint OA pathology. Further investigation is needed to find out the mechanisms of osteoarthritis in this animal model.

REFERENCES

1. Abubaker AO, Hebda PC, Gunsolley JN. (1996). Effects of sex hormones on protein and collagen content of the temporomandibular joint disc of the rat. *J Oral Maxillofac Surg*
2. Allen KD, Athanasiou KA. (2006). Tissue engineering of the TMJ disc: a review. *Tissue Eng*
3. Cledes G, Felizardo R, Foucart JM, Carpentier P. (2006). Validation of a chemical osteoarthritis model in rabbit temporomandibular joint: a compliment to biomechanical models. *Int J Oral Maxillofac Surg*
4. Detamore MS, Athanasiou KA. (2003). Tensile properties of the porcine temporomandibular joint disc. *J Biomech Eng*
5. Dimitroulis G. (2005). The role of surgery in the management of disorders of the temporomandibular joint: a critical review of the literature. Part 2. *Int J Oral Maxillofac Surg*
6. Embree M, Ono M, Kilts T, Walker D, Langguth J, Mao J, et al. (2011). Role of subchondral bone during early-stage experimental TMJ osteoarthritis. *J Dent Res*
7. Kuribayashi A, Okochi K, Kobayashi K, Kurabayashi T. (2008). MRI findings of temporomandibular joints with disk perforation. *Oral Surg Oral Med Oral Pathol Oral Radiol Endod*
8. Kuroki Y, Honda K, Kijima N, Wada T, Arai Y, Matsumoto N, et al. (2011). In vivo morphometric analysis of inflammatory condylar changes in rat temporomandibular joint. *Oral Dis*
9. Suzuki T, Segami N, Nishimura M, Nojima T. (2002). Co-expression of interleukin-1beta and tumor necrosis factor alpha in synovial tissues and synovial fluids of temporomandibular joint with internal derangement: comparison with histological grading of synovial inflammation. *J Oral Pathol Med*