

Eviserasi Usus dan Syok Hemoragik akibat Trauma Tembus Abdomen pada Pasien Lanjut Usia di Daerah Pedesaan: Laporan Kasus

Intestinal Evisceration and Hemorrhagic Shock Due to Penetrating Abdominal Trauma in Elderly Patient at Rural Area: A Case Report

Deny Dwi Hartanto^{1*}, Dony Ruswendro²

¹Department of Emergency Panglima Sebaya Regional Hospital, Paser, East Borneo, Indonesia

²Department of Surgery Panglima Sebaya Regional Hospital, Paser, East Borneo, Indonesia

Article Info

Article History:

Received: December 28, 2023

Accepted: February 19, 2024

Published: February 29, 2024

*)Corresponding author:

E-mail:

dr.denydwihartanto@gmail.com

How to cite this article:

Hartanto, D.D., Ruswendro, D. (2024). Intestinal Evisceration and Hemorrhagic Shock Due to Penetrating Abdominal Trauma in Elderly Patient at Rural Area: A Case Report. *Journal of Agromedicine and Medical Sciences*. 10(1), 12-16

<https://doi.org/10.19184/ams.v10i1.452>

71

Abstrak

Latar Belakang: Trauma tembus seringkali disebabkan oleh kekerasan bersenjata, baik senjata api maupun senjata tajam, dan terjadi pada masyarakat sipil perkotaan. Trauma tembus bertanggung jawab sebesar 15%-45% dari cedera yang terjadi pada masyarakat sipil. **Tujuan:** Tujuan dari makalah ini adalah untuk menyajikan kasus eviserasi usus dan syok hipovolemik akibat trauma tembus abdomen yang terjadi pada pasien lanjut usia di daerah pedesaan. Makalah ini juga menyajikan diskusi tentang pentingnya penanganan kegawatdaruratan yang dapat mengancam jiwa secara memadai sebelum pasien dirujuk ke rumah sakit. **Laporan Kasus:** Dalam kasus ini, trauma tembus terjadi pada pasien lanjut usia akibat luka tusukan pada bagian perut akibat egrek sawit saat memanen buah sawit. Lokasi kejadian berada di kawasan perkebunan kelapa sawit di pedesaan dan jauh dari rumah sakit. Keterbatasan fasilitas resusitasi dan kurangnya sumber daya terlatih di bidang kegawatdaruratan di tempat pasien pertama kali ditangani, mengakibatkan penanganan awal kurang maksimal dan tidak memadai. Hal tersebut mengakibatkan pasien datang ke rumah sakit dalam keadaan syok hipovolemik. **Kesimpulan:** Trauma tembus abdomen yang terjadi pada pasien ini disertai dengan eviserasi usus dan syok hipovolemik yang merupakan indikasi mutlak untuk dilakukan eksplorasi laparotomi segera. Penyakit penyerta pasien berupa gagal jantung kronis dan usia pasien yang tua, perlu menjadi pertimbangan dan perhatian untuk mencegah komplikasi awal dan selanjutnya. Setelah laparotomi, pasien dapat bertahan dan pulih dengan baik tanpa komplikasi apa pun.

Kata Kunci: Trauma Tembus Abdomen, Eviserasi Usus, Laparotomi

Abstract

Background: Penetrating trauma is often caused by armed violence, both firearms and sharp weapons, and occurs in urban civilian populations. Penetrating trauma is responsible for 15%-45% of injuries to civilians. **Aims:** The aim of this paper is to present a case of intestinal evisceration and hypovolemic shock due to penetrating abdominal trauma that occurred in an elderly patient in a rural area. This paper also provides a discussion of the importance of adequately treating life-threatening emergencies before the patient is referred to hospital. **Case Report:** In this case, penetrating trauma occurred in an elderly patient due to an abdominal stab wound caused by a palm sickle when harvesting palm fruit. The location of the incident was in a rural oil palm plantation area and far from the hospital. Limited resuscitation facilities and a lack of trained emergency staff at the public health center where the patient was first treated, resulted in initial treatment being less than optimal and inadequate. This resulted in the patient coming to the hospital in a state of hypovolemic shock. **Conclusions:** The



penetrating abdominal trauma that occurred in this patient was accompanied by intestinal evisceration and hypovolemic shock which was an absolute indication for immediate laparotomy exploration. The patient's comorbidities in the form of chronic heart failure and the patient's elderly age need to be taken into consideration and attention to prevent initial and subsequent complications. After laparotomy, the patient was able to survive and recover well without any complications.

Keywords: Penetrating abdominal trauma, intestinal evisceration, laparotomy.

Introduction

Trauma is one of the most common causes of death worldwide, resulting in five million deaths annually (Alenazi et al., 2019). According to WHO, trauma is the second largest cause of disease, contributing 16% of the global disease burden (Abebe et al., 2019). The abdomen is the area most frequently injured in trauma patients and is the main cause of morbidity and mortality in all age groups in the world (Shabhay et al., 2022). Penetrating trauma is a significant source of morbidity and mortality (Durso et al., 2020). Penetrating trauma is often caused by armed violence, either due to gunshot wounds from firearms or stab wounds from sharp weapons (Robinson et al., 2021). Penetrating trauma is also the fourth most frequent cause of death in patients aged 65 years and over (Student Course Manual ATLS® Advanced Trauma Life Support®, 2018). In this case, penetrating trauma occurred accidentally in an elderly patient due to a work accident in an oil palm plantation. Penetrating abdominal trauma occurred in this patient, accompanied by intestinal evisceration and hypovolemic shock when he arrived at the hospital emergency room.

Case Report

A 68 years old man was brought to the public health center by his co-worker after being hit by a palm knife 30 minutes before admission. Palm knife was fell and hit the lower right quadrant abdomen from 10m highest. Wound was found measuring 6cm x2.5cm with evisceration of the intestine. On examination of vital signs, BP was 90/64 mmHg, pulse 110x/minute, RR 23x/minute, SpO2 98%, warm acral, GCS E4V5M6. The treatment given at the public health center was to obtain

vascular access and administer 250 ml of ringer's lactate fluid, followed by maintenance fluid of 30 drops per minute, 1 ampoule of ranitidine injection, and a urinary catheter has been inserted. The eviscerated intestine was covered with sterile gauze moistened with normal saline because stoma bags were not available. The patient is planned to be referred to the regional general hospital. The distance to the referral hospital is 77 km and can be reached by land ambulance in 1 hour 30 minutes. During on the way to the referral hospital, the eviscerated intestine is periodically moistened with normal saline.

When the patient arrived at the hospital emergency room, the patient's vital signs were BP 80/60 mmHg, pulse 105x/min, RR 28x/min, SpO2 95%, cold acral, visible wounds in the lower right abdominal area accompanied by intestinal evisceration in the wound area. The patient is known to regularly take medication from a cardiologist, including bisoprolol 1x12.5 mg, spironolactone 1x25mg, and atorvastatin 1x25mg, because the patient has a history of chronic heart failure. The patient works as a palm harvester which is related to the stab wounds that occurred. The treatment given when in the emergency room was oxygenation with nasal cannula 4 lpm, administration of 1000ml of Ringer's lactate using two intravenous lines, 1 gram ceftriaxone injection, 40mg omeprazole injection, 30mg ketorolac injection, and insertion of an NGT. Laboratory examination results: WBC 17.33x10³/ul, HB 9.4 g/dl, RBC 3.11x10⁶, HCT 27.5%, Urea 76mg/dl, Creatine 1.2mg/dl. An ECG examination performed on the patient resulted in normal sinus rhythm. The patient was planned to immediately undergo an exploratory laparotomy by the surgeon.

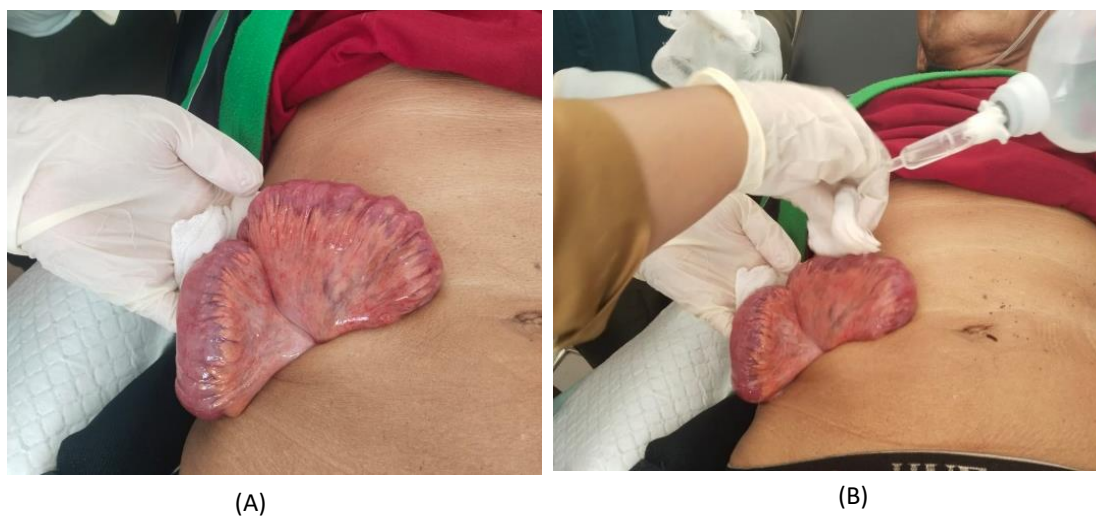

Figure 1. (A) The condition of the stab wound when he first came to the health center, there was visible evisceration of the wound, and (B) The eviscerated intestine is moistened periodically with normal saline and wet gauze

Laparotomy is performed with a midline incision. The eviscerated intestine was then manually returned to its anatomical position. There were no signs of ischemia or perforation or wounds in the eviscerated intestine. During exploration, a t-shaped wound was seen, measuring 6 cm, which penetrated the greater omentum and caused intestinal evisceration. During exploration, a thorough evaluation of all hollow organs and solid intraperitoneal organs is carried out. As a result, there were no injuries to hollow organs and other intraperitoneal solid organs. The puncture wound at the evisceration site and the laparotomy site were then sutured and the surgery was declared complete. Post-operative wounds during treatment in the surgical ward looked clean, there was no seepage of blood or pus, no signs of infection or dehiscence. The patient was declared recovered and could go home to return to the surgical clinic after 6 days of treatment in the surgical ward.

Discussion

Abdominal trauma is responsible for 10% of injury-related deaths. Based on the mechanism of occurrence, abdominal trauma is classified into two categories, namely penetrating trauma and blunt trauma (Naeem *et al.*, 2018). Penetrating trauma includes various mechanisms which can be broadly divided into ballistic trauma (gunshot wounds) and non-ballistic trauma (stab wounds and other punctures) (Durso *et al.*, 2020). Types of penetrating trauma vary in each society based on the accessibility and presence of the type of weapon. According to estimates, 15%-45% of injuries occurring in urban civilians are caused by penetrating trauma. (Hanna *et al.*, 2021). Penetrating trauma in countries with high firearm ownership such as the United States and South Africa is often caused by gunshot wounds. In contrast, in Sub-Saharan Africa, penetrating trauma is often caused by machete or knife wounds because they are cheap and easy to obtain to carry out violence (Robinson *et al.*, 2021). In this case, penetrating trauma occurred due to the palm sickle accidentally hitting the

patient's stomach while working. The palm sickle is a palm oil harvesting tool in the form of a modified sickle with a high support for harvesting palm fruit. Incident occurred in rural area which has 5 km distance from primary health service, and 77 km more to seize Hospital with operating room facilities.

Anatomically, penetrating abdominal trauma will impact the peritoneal cavity and can cause injury to solid organs and other intraperitoneal organs such as major blood vessels and hollow organs (Shabhay *et al.*, 2022). Penetrating abdominal trauma which will be discussed in this case is defined as an injury caused by a sharp object that pierces the skin, causing a wound that has the potential to enter the peritoneum and damage internal abdominal organs (L. Kong *et al.*, 2022). These wounds can damage internal organs or blood vessels, causing infection, shock and even death (Robinson *et al.*, 2021). Management of abdominal stab wounds has evolved over the last three decades (L. Kong *et al.*, 2022). Management can be operative (laparotomy) or non-operative. Generally, laparotomy is required in approximately 25% of abdominal injuries (Abebe *et al.*, 2019). There are three clinical criteria in the initial assessment that are "indications for immediate laparotomy", including peritonitis, unstable hemodynamics and/or evisceration of abdominal visceral organs. Examination of initial vital signs and physical examination of the abdomen upon admission to the hospital emergency room remains the cornerstone of trauma triage (De Robles & Ayuste Jr, 2019). Immediate laparotomy here means that the patient is immediately transferred from the emergency room to the operating room, without additional abdominal imaging examinations. (L. Kong *et al.*, 2022). Although selective nonoperative management of abdominal stab wounds is now widely accepted, organ evisceration after abdominal stab wounds remains an indication for laparotomy (V. Y. Kong *et al.*, 2019). This is because nonoperative management of stable patients with abdominal visceral evisceration has a high failure rate of up to 20% (Mazingi *et al.*, n.d.).

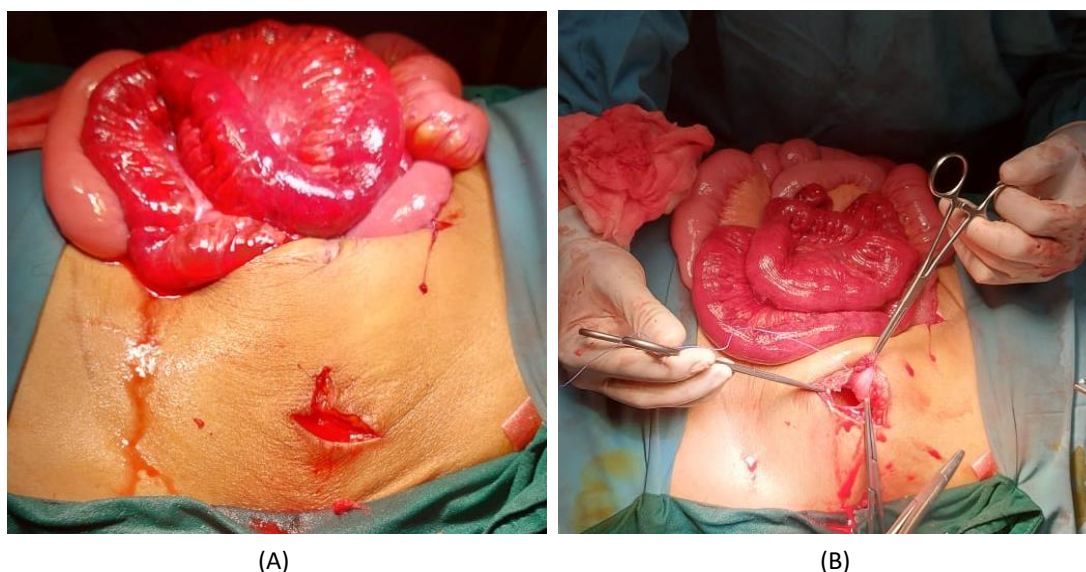


Figure 2. (A) The eviscerated intestine has been returned to the peritoneal cavity and evaluated. (B) Abdominal stab wound appears to penetrate the greater omentum

Initial assessment of patients with abdominal stab wounds, should focus on identifying potentially life-threatening conditions or injuries that require immediate surgical repair (Martin et al., 2018). In this case, the patient arrived at the public health center with an unstable hemodynamic condition, characterized by hypotension, tachycardia, tachypnea. These signs match the clinical signs of class II hemorrhage: 15% to 30% blood volume loss. The first treatment that should be carried out at the public health center is to ensure airway patency with adequate ventilation and oxygenation. Provide additional oxygenation and maintain oxygen saturation to more than 95%. Insertion of vascular access in patients with hypovolemic shock resistance is 2 large intravenous catheters (minimum 18-gauge in adults), but this cannot be done because the items are not available at the public health center. The initial administration of crystalloid fluids is usually 1 liter in adult patients, while monitoring the patient's response to fluid administration by identifying end-organ perfusion and tissue oxygenation and monitoring urine output. Stabilization of the airway, breathing and circulation is still carried out while preparing for referral to a referral hospital (Student Course Manual ATLS® Advanced Trauma Life Support®, 2018). Haste in referring patients to referral hospitals without monitoring and ensuring the patient's condition is stable, including monitoring the condition during in the ambulance, can cause the condition to worsen. In this case, the patient arrived at the hospital emergency room with an unstable hemodynamic condition, which was characterized by hypotension, tachycardia, and cold acral conditions. The most common conditions that occur in penetrating abdominal trauma are large amounts of bleeding or perforation of hollow organs (Martin et al., 2018). In this case, it is suspected that massive bleeding occurred and previous inadequate treatment. All patients who experience organ evisceration after an abdominal stab wound must undergo resuscitation treatment in accordance with the principles of Advanced Trauma Life Support (ATLS) (V. Y. Kong et al., 2019). Antibiotics Prophylactic administration, soaking with normal saline, and wound debridement can help prevent complications in cases of penetrating trauma (Mazingi et al., n.d.). There are two types of eviscerations due to penetrating abdominal trauma, namely evisceration of organ contents, where the viscus herniates through a defect in the abdominal wall, and salvaged omentum evisceration, where part of the greater omentum herniates through the defect. There is a general consensus that organ evisceration requires surgical exploration (V. Kong et al., 2023).

Sharp force injuries (incised wound) with evisceration cases associated with small intestine, large intestine, and gaster are 70%, 26% and 3%, respectively. (V. Y. Kong et al., 2019). Meanwhile, injuries to intraperitoneal organs that often occur are the small intestine (50%), large intestine (40%), liver (30%), and blood vessel system (25%) (Hanna et al., 2021). The evisceration that occurred in this case was of the large intestine without isolation of the omentum. If organ evisceration occurs due to penetrating abdominal trauma, the organ is wrapped in a sterile transparent and non-adhesive plastic dressing (V. Y. Kong et al., 2019). Penetrating abdominal trauma accompanied by intestinal evisceration can result in ischemic damage due to impaired blood circulation and

strangulation of the eviscerated intestine in the area where the wound occurred (Lee et al., 2018). Unstable hemodynamics with signs of shock is a clear warning sign of ongoing massive bleeding and requires immediate exploratory laparotomy along with resuscitation using blood products (Martin et al., 2018). Bleeding must be suspected and alerted in these patients, because bleeding is the most frequent cause of shock in trauma patients (Student Course Manual ATLS® Advanced Trauma Life Support®, 2018). Although there is no consensus regarding the definition of "unstable", most studies have used hypotension with a systolic blood pressure of less than 90 or 100 mmHg for adult patients (Martin et al., 2018). The decision to perform immediate laparotomy was the right decision, because two of the patient's three clinical criteria had been met. When a laparotomy is performed, the eviscerated organs are returned to the peritoneal cavity and examined again. All wounds that occur are repaired and the eviscerated organs are placed in the appropriate anatomical position in the abdominal cavity (V. Y. Kong et al., 2019). Luckily, even though the stab wound that occurred in this patient was quite deep, even penetrating the greater omentum, this patient did not suffer serious injury to the eviscerated intestine or other intraperitoneal organs.

One in five patients with penetrating abdominal trauma is reported to experience postoperative complications. This occurs especially in patients with severe injuries and physiological disorders (Hanna et al., 2021). The reported incidence of early complications of laparotomy or anesthesia varies between 8.6% and 25.6%. The incidence of late complications such as intestinal obstruction due to postoperative adhesions and incisional hernia is reported to be between 2.4% and 5% (De Robles & Ayuste Jr, 2019). Predisposing factors that can cause complications in cases of penetrating abdominal trauma include fecal contamination, foreign bodies, multiple visceral injuries, extensive peritoneal contamination, anastomotic leakage, and continuous bleeding. Complications that may occur in cases of penetrating abdominal trauma are intra-abdominal abscesses (Hanna et al., 2021). In this case, the patient's condition after surgery improved and he did not experience any initial or subsequent complications. The patient's comorbidity was chronic heart failure, which did not cause complications perioperatively, during surgery, or worsen post-operatively.

Conclusion

Penetrating abdominal trauma with unstable hemodynamic conditions and evisceration of intraperitoneal organs is an absolute indication for immediate exploratory laparotomy. Appropriate and adequate initial treatment for life-threatening conditions must still be carried out as best as possible in rural area health centers, even if facilities and resources are limited. It is mandatory to stabilize the patient's clinical condition, especially conditions that can be life-threatening before referring penetrating abdominal trauma patients to a surgeon at the referral hospital. Comorbidities and the patient's age must be taken into consideration and special attention in the management of penetrating abdominal trauma patients, so that initial and subsequent complications can be prevented.

Conflict of interest

The authors declare no conflict of interest.

Acknowledgments

There is no acknowledgement in this case reports.

Reference

- Abebe, K., Bekele, M., Tsehaye, A., Lemmu, B., & Abebe, E. (2019). Laparotomy for Abdominal Injury Indication & Outcome of patients at a Teaching Hospital in Addis Ababa, Ethiopia. *Ethiopian Journal of Health Sciences*, 29(4), 503–512. <https://doi.org/10.4314/ejhs.v29i4.12>
- Alenazi, A. K., Almutairi, N. A., Alhuzaimi, Y. K., Altamimi, S. S., Alayed, Y. S., & Alanazi, Z. G. (2019). The nature and severity of stab wounds at tertiary care hospitals in Kingdom of Saudi Arabia. *Pan African Medical Journal*, 34. <https://doi.org/10.11604/pamj.2019.34.212.20533>
- De Robles, M. S. B., & Ayuste Jr, E. C. (2019). Mandatory Laparotomy in Penetrating Abdominal Injuries with Omental Evisceration: Experience in a Major Trauma Center in the Philippines. *Cureus*. <https://doi.org/10.7759/cureus.5688>
- Durso, A. M., Paes, F. M., Caban, K., Danton, G., Braga, T. A., Sanchez, A., & Munera, F. (2020). Evaluation of penetrating abdominal and pelvic trauma. *European Journal of Radiology*, 130. <https://doi.org/10.1016/j.ejrad.2020.109187>
- Hanna, K., Asmar, S., Ditillo, M., Chehab, M., Khurram, M., Bible, L., Douglas, M., & Joseph, B. (2021). Readmission With Major Abdominal Complications After Penetrating Abdominal Trauma. *Journal of Surgical Research*, 257, 69–78. <https://doi.org/10.1016/j.jss.2020.07.060>
- Kong, L., Kong, V. Y., Christey, G., Ah Yen, D., Amey, J., Denize, B., Marsden, G., & Clarke, D. (2022). Clinical decision making for abdominal stab wounds in high resourced but low volume centers require structured guidelines to be effective. *Surgery in Practice and Science*, 10. <https://doi.org/10.1016/j.sipas.2022.100087>
- Kong, V., Cheung, C., Rajaretnam, N., Sarvepalli, R., Xu, W., Bruce, J., Laing, G., & Clarke, D. (2023). Laparotomy for Abdominal Stab Wound With Combined Omental and Organ Evisceration: 10-Year Experience From a Major Trauma Centre in South Africa. *American Surgeon*, 89(4), 650–655. <https://doi.org/10.1177/00031348211031855>
- Kong, V. Y., Weale, R., Blodgett, J. M., Buitendag, J., Bruce, J. L., Laing, G. L., & Clarke, D. L. (2019). Laparotomy for organ evisceration from abdominal stab wounds: A South African experience. *Injury*, 50(1), 156–159. <https://doi.org/10.1016/j.injury.2018.08.003>
- Lee, C. K., Park, C. Y., Yeo, K. H., & Kim, H. H. (2018). Stab Wound Extension for the Eviscerated Small Bowel with Severe Ischemic Changes. *JOURNAL OF ACUTE CARE SURGERY*, 8(2), 71–73. <https://doi.org/10.17479/jacs.2018.8.2.71>
- Martin, M. J., Brown, C. V. R., Shatz, D. V., Alam, H. B., Brasel, K. J., Hauser, C. J., De Moya, M., Moore, E. E., Rowell, S. E., Vercruyssen, G. A., Baron, B. J., & Inaba, K. (2018). Evaluation and management of abdominal stab wounds: A Western Trauma Association critical decisions algorithm. *Journal of Trauma and Acute Care Surgery*, 85(5), 1007–1015. <https://doi.org/10.1097/TA.0000000000001930>
- Mazingi, D. S., Mutambanengwe, P., Zimunhu, T., Gwatarisa, T., Mbuwayesango, B. A., Munanzvi, K., Muparadzi, ; Constantine, Moyo, ; Mugove, & Mwanza, Y. (n.d.). *Intestinal Evisceration in Children From the Bite of the Domestic Pig, Sus scrofa domesticus: A Report of Two Cases*.
- Naeem, B. K., Perveen, S., Naeem, N., Ahmed, T., Khan, I., Khan, I., Tahir, M., & Iqbal, M. (2018). Visceral Injuries in Patients with Blunt and Penetrating Abdominal Trauma Presenting to a Tertiary Care Facility in Karachi, Pakistan. *Cureus*. <https://doi.org/10.7759/cureus.3604>
- Robinson, B., Purcell, L. N., Kajombo, C., Gallaher, J., & Charles, A. (2021). Outcomes of stab wounds presenting to kamuzu central hospital in Malawi. *Malawi Medical Journal*, 33(1), 1–6. <https://doi.org/10.4314/mmj.v33i1.1>
- Shabhay, A., Shabhay, Z., Chilonga, K., Mwakyembe, T., Msuya, D., Massaga, F., & Chugulu, S. (2022). Potential Spectrum of Accompanied Penetrating Abdominal Intraperitoneal Injuries with Bowel Evisceration: Surprises Awaiting the Trauma Surgeon in Resource Limited Settings. *Case Reports in Surgery*, 2022, 1–7. <https://doi.org/10.1155/2022/8015067>
- Student Course Manual ATLS® Advanced Trauma Life Support*®. (2018).